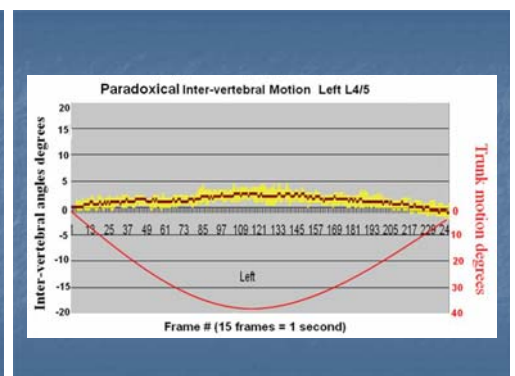
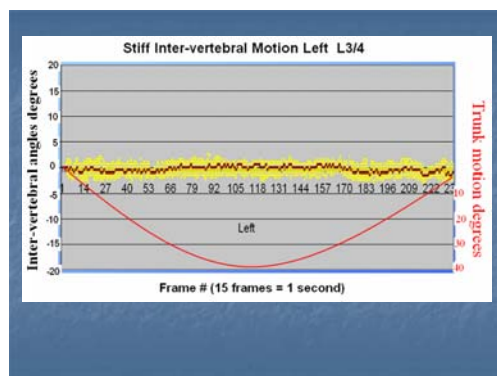
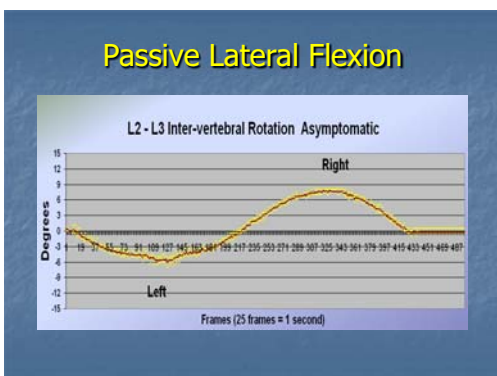
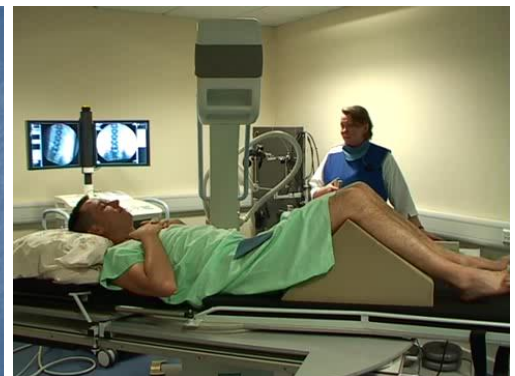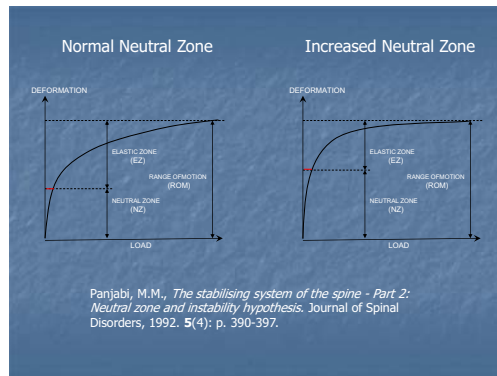
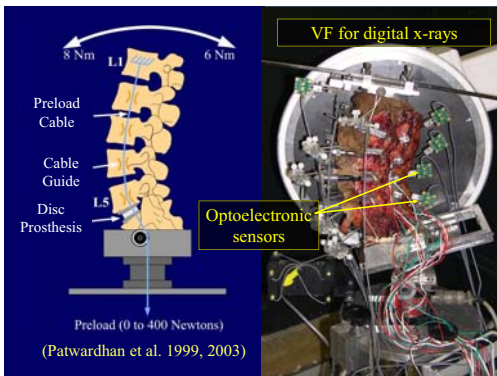
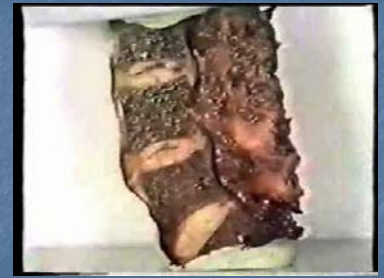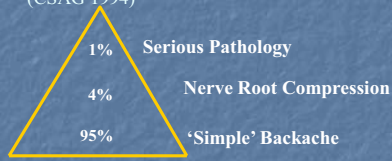
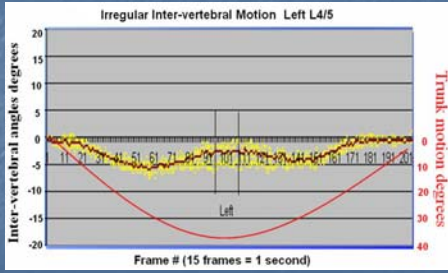


A Quantitative Fluoroscopy Method for the Diagnosis of Mechanical Back Pain

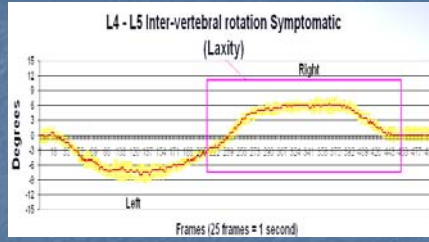
Alan Breen DC PhD
Professor of Musculoskeletal Health Care
AECC, Bournemouth, UK

Diagnostic categories of back pain (CSAG 1994)



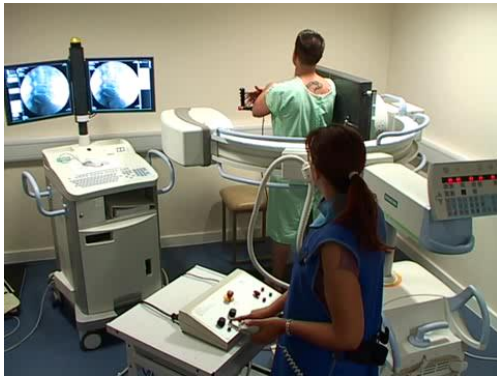

Laxity

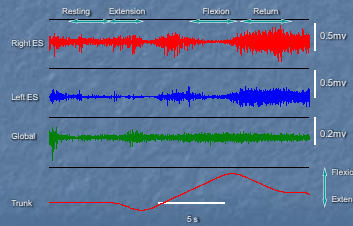


Breen AC, Muggleton JM, Mellor FE. An objective spinal motion imaging assessment (OSMIA): Reliability, accuracy and exposure data. BMC Musculoskeletal Disorders 2006;7:1.

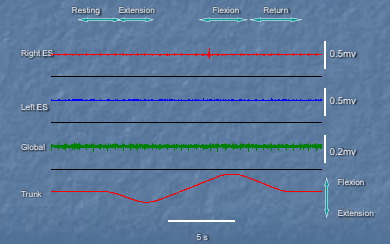
	Reliability (Mean squares)	Accuracy (Mean squares)	Dosage (mSV)
Coronal plane	1.86°	0.32°	0.9
Sagittal plane	1.94°	0.54°	1.7



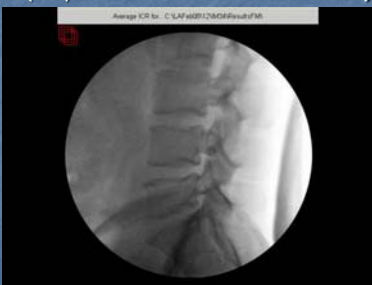Flexion-extension Control example – weight-bearing sEMG



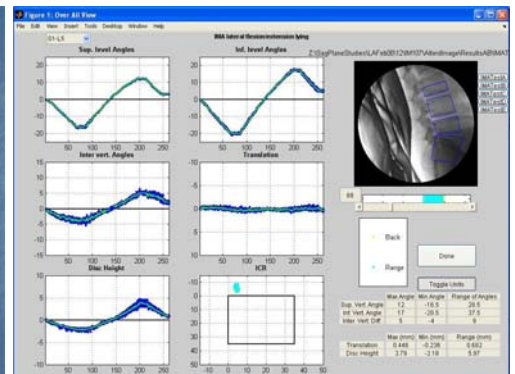
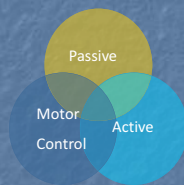
Recumbent flexion-extension – control example



Abnormal load distribution (Sequential CORs in lumbar flexion)



Inter-vertebral Motion Subsystems (Panjabi 1992)

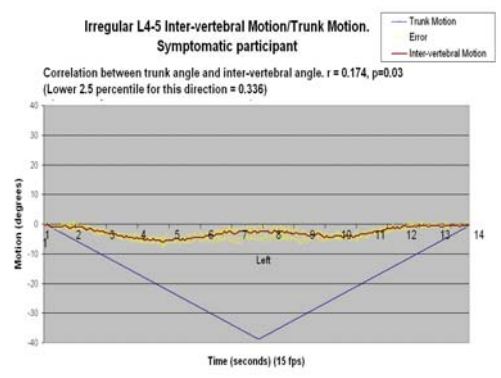
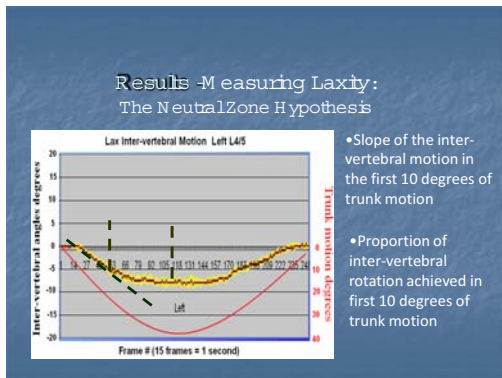
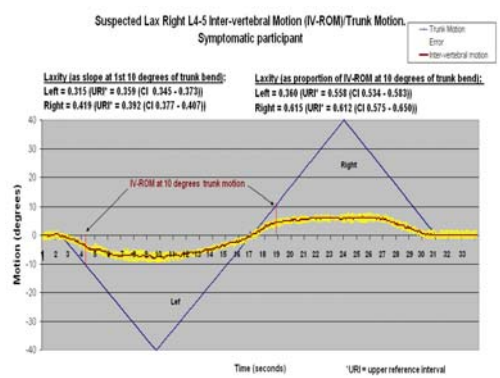
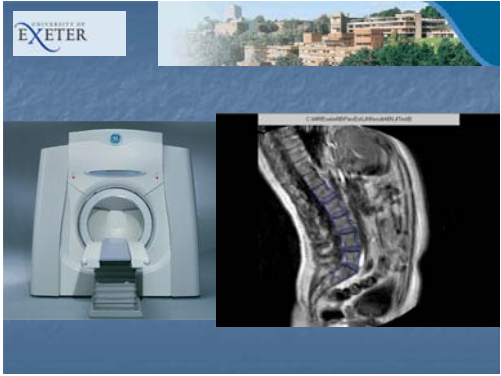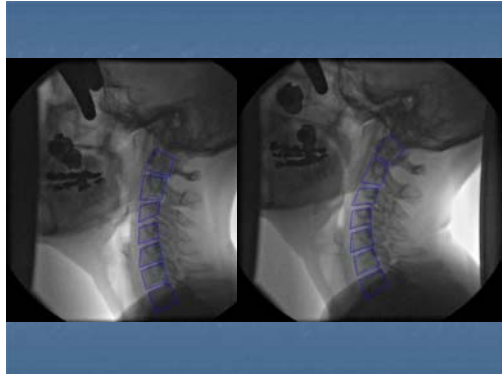
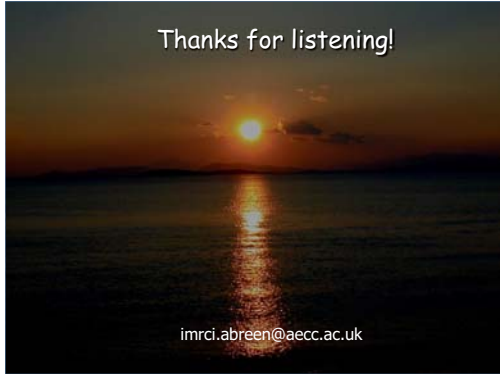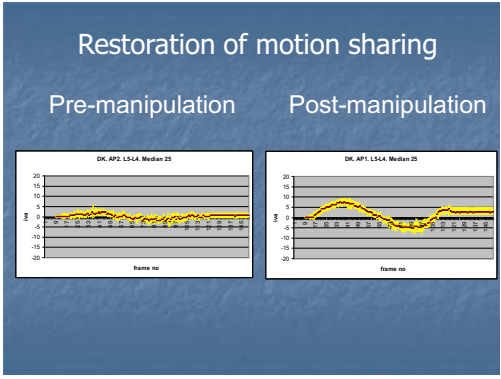
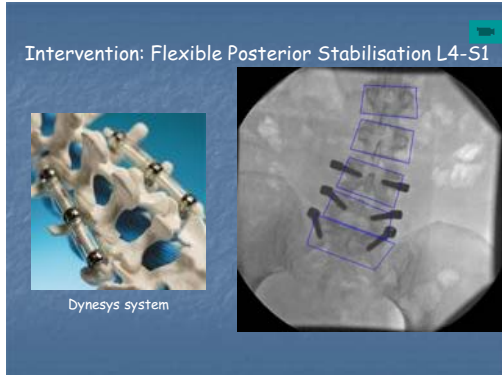




International Networking

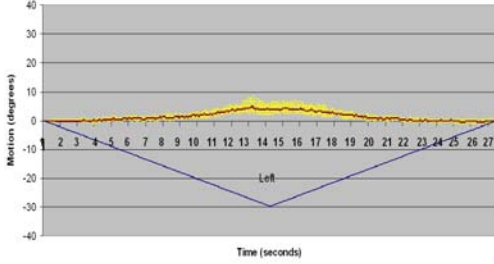
**First International Forum on Quantitative Fluoroscopy of the Spine
San Francisco – Aug 2009**

- Breen AC, Muggleton JM, Mellor FE. An objective spinal motion imaging assessment (OSMA): Reliability, accuracy and exposure data. BMC Musculoskeletal Disorders 2006;7:11.
- Mellor FE, Muggleton JM, Bagust J, Mason W, Thomas PW, Breen AC. Mid-lumbar lateral flexion stability measured in healthy volunteers by in vivo fluoroscopy. Spine (in press)
- Teyhan DS, Flynn TW, Bovik AC, Abraham LD. A new technique for digital fluoroscopic video assessment of sagittal plane lumbar spine motion. Spine. 2005;30(14):E406-E13.
- Wong KWN, Luk KDX, Leong JOY, Wong SF, Wong KKY. Continuous dynamic spinal motion analysis. Spine. 2005;31(4):414-9.
- Daltz AK, Breen AC, Mellor FE, Teyhan DS, Panjabi MM, Wong KWM. Kinematics of the Aging Spine: A Review of Past Knowledge and Survey of Recent Developments, with a Focus on Patient-Management Implications for the Clinical Practitioner in: Yue, Geyer, Johnson, Khoo & Hochschuler. The Comprehensive Treatment of the Aging Spine: Minimally Invasive and Advanced Techniques. (in press)



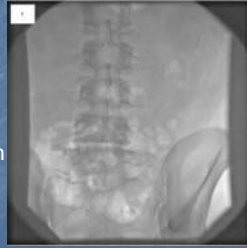Paradoxical L4-5 Inter-vertebral Motion/Trunk Motion. Symptomatic participant

Correlation between trunk angle and inter-vertebral angle. $r = -0.893$
(Lower 2.5 percentile for this direction = 0.336)


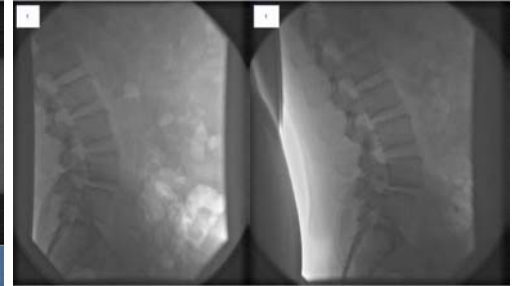


Pt 1 – Male with chronic back pain and L4-5 spondylolisthesis with pars defect

- Age 58
- School cleaner
- Chronic back pain 20 years
- Recent exacerbation 4 weeks
- Off work
- VAS 7/10



Passive recumbent motion Flexion Extension



OSMA Inter-vertebral Motion Report

Age: 58, Sex: M, Date of Birth: 1948, Date of Investigation: November 2008

Clinical Notes: L4-5 spondylolisthesis, Pars defect

Acquisition type: Passive, recumbent, Grade scale: 100%

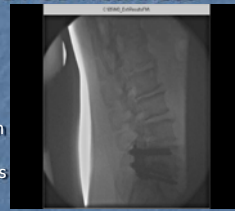Trunk Range Obtained: Coronal Left 50° Right 60°, Sagittal Flexion 60° Extension 40°

Level	Left	Right	Flexion	Extension
L2-3	L1 set a field of view	L1 set a field of view	Failed	Failed
L3-4	Failed	Failed	Failed	Failed
L4-5	Failed	Failed	Failed	Failed
L5/S1	Failed	Failed	Failed	Failed

OSMA, Right L5/S1 has error value of 2.2 but based only on one tracking and sample taken. Please see another set before this to be a stiff segment.

Pt 2 - Male with chronic back and leg pain and left L4-S1 weakness

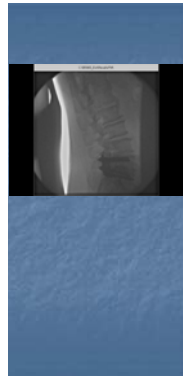
- Age 59
- Retired warehouse man
- Chronic back pain 30 yrs
- L5-S1 PLF 2005
- Additional thigh and leg pain past 4 years
- Walking distance 200 metres
- VAS 6.5/10
- Patellar and achilles' absent



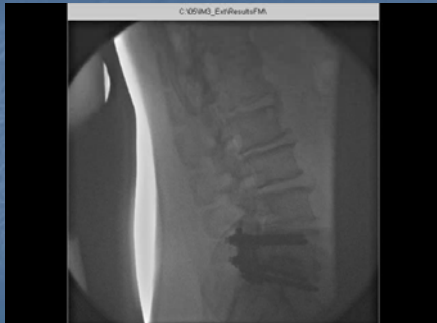OSMA Inter-vertebral motion report

OSMA, L5/S1 has error value of 2.2 but based only on one tracking and sample taken. Please see another set before this to be a stiff segment.

Level	Left	Right	Flexion	Extension
L2-3	Failed	Failed	Failed	Failed
L3-4	Failed	Failed	Failed	Failed
L4-5	Failed	Failed	Failed	Failed
L5/S1	Failed	Failed	Failed	Failed



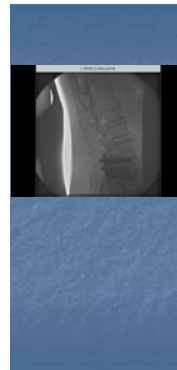L2-3 Extension ICR locus



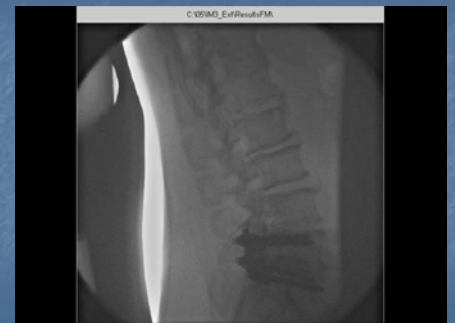OSMA Inter-vertebral motion report

OSMA, L5/S1 has error value of 2.2 but based only on one tracking and sample taken. Please see another set before this to be a stiff segment.

Level	Left	Right	Flexion	Extension
L2-3	Failed	Failed	Failed	Failed
L3-4	Failed	Failed	Failed	Failed
L4-5	Failed	Failed	Failed	Failed
L5/S1	Failed	Failed	Failed	Failed

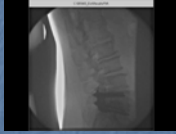

L3-4 Extension ICR locus

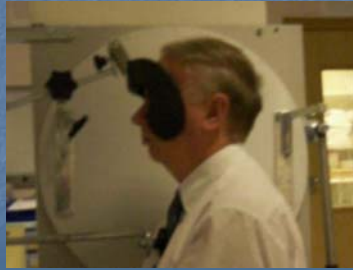


Case management

- L2-3 mobilisation
 - Flexion distraction
 - Bilateral spinous hooks
- 6 sessions over 4 weeks
- VAS 2/10
- Heel and toe walk improved
- Walking distance 3 km



Controlled acquisition: cervical weight-bearing



When to consider

Problem spinal pain cases where:

Mechanical pain but no improvement and becoming chronic

Spinal pain that constantly recurs

Poor response to spinal surgery

Laxity or altered dynamic load bearing as a pain source?

Mechanical pain and considering referral to surgeon



in the new AECC Clinic

